

# First report of Saprolegniosis on eggs and a juvenile of “Argentinian silverside” (*Odonthestes bonariensis*)

S.G. Pacheco Marino <sup>1\*</sup>, M.M. Steciow <sup>1</sup> and C. Barbeito<sup>2</sup>

<sup>1</sup> Instituto de Botánica Spegazzini, UNLP, 53 N° 477, (1900) La Plata, Argentina; <sup>2</sup> Cátedra de Histología y Embriología Facultad de Ciencias Veterinarias, UNLP, 60 y 118 s/n, (1900); La Plata, Argentina.

## Abstract

*Odonthestes bonariensis* is a freshwater teleost fish from the Pampean inland waters, with an important economic potencial. The conditions of its intensive culture systems favour the proliferation of pathogen agents. This work describes the occurrence of *Achlya racemosa* Hildebrand on eggs, and of *Saprolegnia ferax* (Gruith.) Thuret on a juvenile of Argentinian silverside (*Odonthestes bonariensis*). These represent new records for Argentina and are reported for the first time as agents of saprolegniosis for this native freshwater fish.

## Introduction

Water molds of the class Peronosporomycetes, Kingdom Straminipila (Dick, 2001), have long been known as external parasites of freshwater and estuarine fishes, crustaceans, amphibians and reptiles, and notably as causal factors of saprolegniosis (Noga, 1993).

These organisms are distributed worldwide, and three orders have been shown to have species capable of infecting living fishes and their eggs: Saprolegniales, Leptomitales and Peronosporales (Noga, 1993). These genera are considered to be saprotrophic water molds and are normal ubiquitous components of freshwater ecosystems. Despite existing evidence that water molds may require the presence of environmental conditions or other pathogens to cause ulcerative mycosis, some species, such as *Aphanomyces invadans* and

*Saprolegnia parasitica*, appear to be highly pathogenic; in addition, under intensive rearing conditions, other species may act as primary pathogens (Chacko, 1993).

Saprolegniales are very important pathogens of fish eggs (Czeczuga et al., 2001, Chukanhom & Hatai, 2004). Infections are believed to begin in unfertilized or non-viable eggs. However, once established, the fungi rapidly spread to adjacent normal healthy eggs, eventually resulting in complete loss of the brood (Noga, 1993). These pathogens cause population declines in natural environments, but their pathogenicity is more important in culture conditions, under which they are known to cause the mortality of up to 80 -100% of incubated eggs (Chukanhom & Hatai, 2004).

\* Corresponding author's E-mail: suani.pm@gmail.com

Argentinian silverside *Odontheistes bonariensis* Cuv. & Val. (Pisces, Atherinopsidae), is one of the most important fish species for inland fisheries aquaculture in both Argentina and Japan (Kitanchoren et al., 1995). Consequently, there exists considerable interest in the development of intensive breeding of this fish; unfortunately, under intensive culture conditions, silversides are vulnerable to several diseases, including saprolegniosis. Some contributions have highlighted the importance of fungal diseases for this native Argentinian fish and its eggs, but with no mention or identification of the etiological agent, and until now, no systematic studies have been made of the species responsible for saprolegniosis in this host (García Romero, 2001, Mancini et al., 2006). Because fungal species on fish eggs have rarely been investigated in Argentina, we studied the mycobiota of this species.

The goal of this contribution is to report and characterise two Argentinian strains of aquatic fungi: *Achlya racemosa* Hildebrand and *Saprolegnia ferax* (Gruihth.) Thuret as etiological agents of saprolegniosis on eggs and juveniles of Argentinian silverside from Buenos Aires province (Argentina).

## Material and methods

### *Samples of studied biological material*

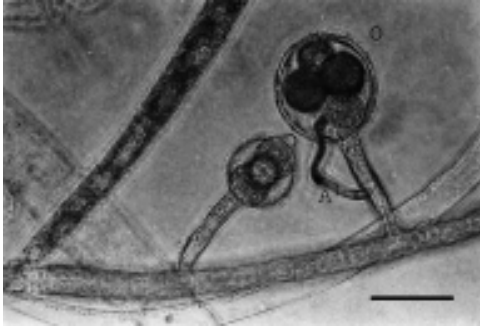We investigated eggs from Argentinian silverside (*Odontheistes bonariensis*) gathered from the Chascomús Fisheries Experimental Station, located in Chascomús county (Buenos Aires province, Argentina). Weekly samplings of approximately 200 to 300 eggs were made during six weeks at the end of the southern spring. Initially the eggs were collected and brought to the laboratory in sterile glass bottles. Eggs were kept in 2 L. plastic

incubating tanks with flowthrough water (complete turnover every 8 h) and constant aeration. During incubation, infected eggs covered in white cottony fungal mycelium were detected, collected using a sterile plastic pipette, and kept separately. The infected eggs were kept separately in Petri dishes with sterilized distilled water and sesame seeds used as baits for posterior isolation of the causal agent.

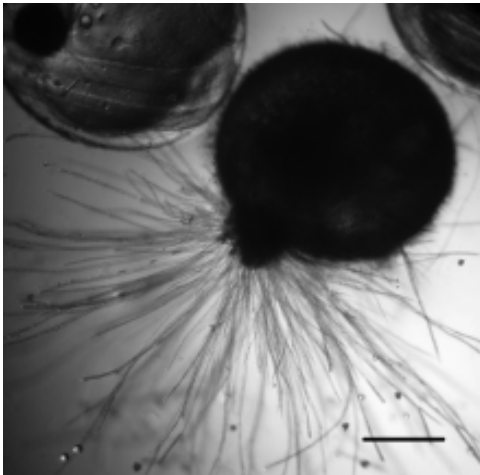
Two months after incubation, a juvenile silverside specimen was observed to have a perianal lesion covered by abundant mycelium. After the death of the specimen, mycelium samples were collected and placed in Petri dishes with distilled water and sterile sesame seed baits.

### *Isolation and identification of fungal strains*

Fungal strains were isolated following the method described by Johnson et al. (2002). All samples were kept in sterile Petri dishes, in water containing some seeds and incubated at room temperature (15-20 °C). Once the seeds were colonized by the fungal hyphae, a small portion of mycelium was aseptically transferred to a cornmeal agar (CMA) medium. The strains were purified by repeatedly subculturing the colonies onto cornmeal agar plates with 1 ml antibiotic solution (1 g streptomycin sulfate, 0.5 g chloramphenicol in 200 ml distilled water). Morphological studies were performed on these colonies in water cultures on hemp seeds. Measurements such as diameter of fungal colonies, diameter of oogonia, number of oospores per oogonia, and diameter of oospores were calculated from 50 counts of each of three replicates, made using an Olympus BX 40 microscope equipped with phase contrast optics.



**Figure 1.** *Achlya racemosa*. Detail of mycelium with characteristic oogonia (O) containing oospores inside and androgynous antheridial branches (A). Scale bars = 10  $\mu$ m.



**Figure 2.** *Odontesthes bonariensis*. Eggs infected by *Achlya racemosa*. Scale bars = 0.25mm.

### *Histopathological study*

Affected and unaffected eggs were fixed by immersion in 10% phosphate-saline buffered formalin. The fixed samples were processed and embedded in paraffin wax according to standard procedures. Sections (5 $\mu$ m) or each were stained with hematoxylin and eosin (H&E) and a silver methenamine satining (Grocott) as described by Prophet et al., 1992, and examined by light microscopy.

The type specimen is deposited in the mycological herbarium of the Spegazzini Institute (LPS) culture collection.

### **Results**

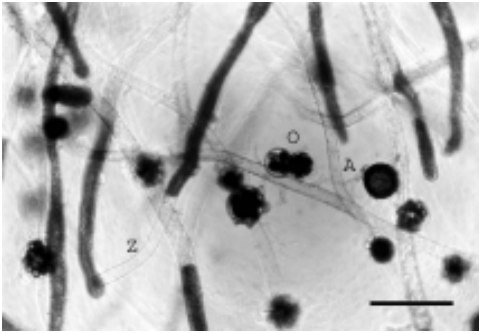
#### *Description of species*

*Achlya racemosa* Hildebrand, Jahrb. Wiss. Bot. 6:249. 1867-68 (Figures 1-2).

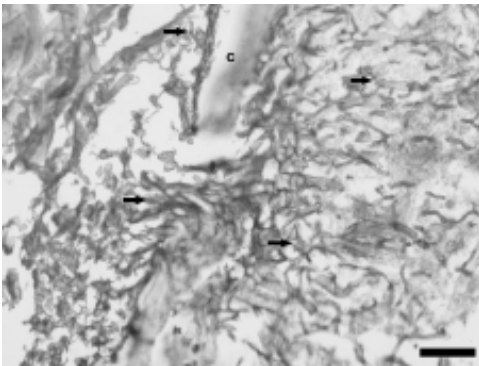
Monoecious. Main hyphae stout, sparingly branched and measuring 20-120  $\mu$ m diam. at base. Zoosporangia abundant or rare; cylindrical or filiform, straight, bent or sinusoid, with characteristic tapering towards the tips which can be also straight or curved; very rarely branched; renewed sympodially or in basipetalous succession; (200-) 300-400 (-900) X (14-) 20-35 (-45)  $\mu$ m. Zoospore discharge and behaviour achlyoid; primary spore cysts 8-12  $\mu$ m diam. Gemmae, when present, usually scanty or sparse; very variable in form and position. Oogonial lateral, terminal or intercalary, often racemosely arranged; spherical or obpyriform; (-30) 36-70  $\mu$ m diam. Oogonial wall pitted or unpitted; smooth on outer surface, slightly irregular on inner surface. Oogonial stalks 100-300  $\mu$ m long. Oospores centric or subcentric; spherical or ellipsoidal; (1-) 2-6 (-11) per oogonium; (14-) 15-26 (-32)  $\mu$ m diam. Antheridial branches predominantly androgynous, infrequently exiginous (semihipogynous), extremely rarely diclinous.

*Saprolegnia ferax* (Gruith.) Thuret, Ann. Sci. Nat. Bot. 14:229. 1850 (Figure 3).

Specimens examined: ARGENTINA. Buenos Aires. Chascomús county (partido): Fisheries Experimental Station, December 2005, from silverside eggs (LPS N° 1019).



**Figure 3.** *Saprolegnia ferax*. Aspect of mycelium in water culture, with antheridial branches (A) Zoosporangia (Z), and oogonia containing oospores inside (O). Scale bars = 50  $\mu$ m.



**Figure 4.** *Odontesthes bonariensis*. Transversal section of egg staining with Grocott technique shows hyphae penetrating the corion (C). Scale bars = 50  $\mu$ m.

Monoecious. Mycelium stout, hyphae moderately to sparsely branched. Zoosporangia cylindrical, clavate, fusiform, or slightly irregular; straight, bent or sigmoid; renewed internally, rarely in a basipetalous or cymose manner; (30-) 400-600 (-900) X 16-48  $\mu$ m. Zoospores dimorphic; discharge and behavior saprolegnoid; primary spore cysts 9-12  $\mu$ m diam. Gemmae, when present, variable in form and position. Oogonia lateral, terminal or intercalary; pyriform, spherical or subspherical, often dolioform when intercalary; (28-) 60-80 (-120)  $\mu$ m diam. Oogonial wall pitted, rarely unpitted; smooth

or rarely with one or two short, papilliform evaginations, or apiculate. Oogonial stalks 20-300  $\mu$ m in length. Oospores centric or subcentric, spherical or ellipsoidal; (1-) 10-35 per oogonium, 20-25 (-31)  $\mu$ m diam. Antheridial branches predominantly monoclinal or androgynous, rarely diclinal; sometimes absent.

Specimens examined: ARGENTINA. Buenos Aires. Chascomús county (partido): Fisheries Experimental Station, May 2006, from water, parasitic on a juvenile silverside (LPS N° 1020).

#### *Histopathological study*

The histological study showed the presence of structures resembling hyphae surrounding the egg in H&E. These structures stained intensely with Grocott staining. Zones of discontinuity were observed in the corion which are the points of penetration of hyphae, with an expansive growth inside the egg. Fig. 4 shows the presence of fungi surrounding the egg and inside it. A loss of the embryonic tissue organization is also observed in the affected eggs.

#### **Discussion and conclusions**

The term saprolegniosis designates the fungal diseases caused by fungi of the Order Saproleginales. These infections are characterized by fungal growth on the body surface of the fish, evident as patches of white to brownish cottony growth on the affected zone. These lesions tend to become chronic and facilitate the entrance of other pathogens. The infection, whether occurring in isolated individuals or in epidemic proportions, is preceded by some environmental disturbance that disrupts homeostasis of the fish host.

Fungal infection is more difficult to occur in adult fish than in eggs because the fish would have an unspecific immune response against spore colonization; it has been shown that the mucus of salmonids may contain a morphogen capable of inhibiting spore germination (Chacko, 1993).

These fungi have an important effect on fish eggs, especially in fish hatcheries. Saprolegniosis on fish eggs is profusely recorded; *Achlya racemosa* and *Saprolegnia ferax* have been found as parasites of a wide variety of fish eggs (Ogbonna y Alabi, 1991; Czczuga et al., 2001; Johnson et al., 2002).

*A. racemosa* has been previously mentioned as parasitic on other fish species, such as *Catla catla* and *Anguila japonica* and also on the eggs of salmonids, *Tilapia* sp. and other fish species (Ogbonna & Alabi, 1991; Johnson et al., 2002).

In a previous contribution dealing with other Saprolegniales species infecting *O. bonariensis*, which was introduced in Japan as an exotic species, saprolegniosis was usually seen on the pectoral fins, caudal peduncle and oral area of the Argentine silverside (Hatai et al., 1993). One case of saprolegniosis associated with *Aeromonas* in *Odonthestes bonariensis* was investigated by Lawhavinit (1987), while Hatai et al. (1990) recorded the isolation of *S. parasitica* from a silverside hatchery in the Kanagawa Prefecture, Japan. Kitancharoen et al. (1995) studied some morphological aspects of *Saprolegnia dicilina* type 1, isolated from hemorrhagic lesions in the mouth and caudal fin of silversides, which affected more than 50% of the silverside population from the Tochigi Prefecture Fisheries Station.

Several isolates of *Saprolegnia*, *Aphanomyces*, *Pythium*. and *Achlya* were found in the studied egg samples, which failed to produce oogonia and antheridia and were therefore impossible to identify to the species level. However, *Achlya racemosa* was the prevalent species isolated from eggs.

In this isolate of *Achlya racemosa*, the zoosporangia were typically cylindrical or filiform, straight, bent or sinusoid, with characteristic tapering towards the tips, a feature not observed by Johnson et al. (2002), and they were also smaller, as were also the oogonia and oospores.

This is first report of saprolegniosis in silverside eggs and juveniles from Buenos Aires province (Argentina), as well as is the first report of *Achlya racemosa* and *Saprolegnia ferax* for this country. Thus, this contribution expands the list of hosts recorded for both pathogens and extends their distribution in the American continent, since it is the southernmost report for these species. The species had never been previously reported as a fish parasite in South America and this is the first description of the histopathological alterations in embryoned eggs of pejerrey infected by *Saprolegnia*, similar findings have been reported by Panchani et al. (2007), in eggs of tilapia (*Oreochromis niloticus* Linn.) infected by several species of the *Saprolegniaceae* family.

One of the aims of this study is alerting the veterinary community about the relevance of opportunistic fungi, such as *Saprolegnia* and *Achlya* species, as causal agents of saprolegniosis. The emergence of these species as infectious agents for fish highlights

the importance of correct etiological identification, which in turn allows for appropriate treatment of the disease.

### Acknowledgements

The work of S.G.P.M., M.M.S. and C.B. was partly funded by CONICET. This work was funded by Universidad Nacional de La Plata (N11/ 440 and SPU /PPUA 575/07) and CONICET (PIP 5931). We thank the Chascomús Fisheries Experimental Station for providing the biological material.

### References

Chacko JA (1993). Fungal and algal diseases of Salmonids. In **"Fish Medicine"** (M.K. Stoskopf, Ed.). W.B. Saunders Company: Philadelphia.

Chukanhom K & Hatai K (2004). Freshwater fungi isolated from eggs of the common carp (*Cyprinus carpio*) in Thailand. *Mycoscience* **45**, 42-48.

Czczuga B, Pietrucha M & Muszyńska E (2001). Zoosporic fungi growing on the eggs of *Coregonus Lavaretus* Maraena (Block, 1779) from lake Miedwie in Pomerania. *Acta Ichthyologica et Piscatoria* **31**(1), 141-150.

Dick MW (2001). Straminipilous Fungi. Systematic of the Peronosporomycetes including accounts of the marine Straminipilous Protists the Plasmodiophorids and similar Organisms. Dordrecht. Kluwer Academic Publishers.

García Romero N (2001). Alteraciones patológicas del pejerrey (*Odontesthes bonariensis* C.) en ambientes naturales y bajo condiciones de cultivo. In **"Fundamentos Biológicos, Económicos y Sociales para una Correcta Gestión del Recurso Pejerrey"** (F. Grossman, Ed.). Editorial Astyanax. Azul, AR.

Hatai K, Willoughby LG & Beakes GW (1990). Some characteristics of *Saprolegnia* obtained from fish hatcheries in Japan. *Mycological Research* **94**(2), 182-190.

Hatai K, Labvhavit O, Toda K & Sugou Y (1993). Mycobacterium infection in pejerrey, *Odontesthes bonariensis* Cuvier Valenciennes. *Journal of Fish Diseases* **16**, 397-402.

Johnson Jr TW, Seymour RL & Padgett DE (2002). Biology and Systematics of the Saprolegniaceae. <http://dl.uncw.edu/digilib/biology/fungi/taxonomy%20and%20systematics/padgett%20book/>.

Kitancharoen N, Yuasa K & Hatai K (1995). Morphological aspects of *Saprolegnia diclina* Type 1 isolated from pejerrey *Odontesthes bonariensis*. *Mycoscience* **36**, 365-368.

Lawhavit O, Hatai K & Kubota SS (1987). Studies on Fungus Diseases of Pejerrey *Odontesthes bonariensis* (C & V). I: *Aeromonas hydrophila* Isolated from Pejerrey with Saprolegniosis. *The bulletin of the Nippon Veterinary and Zootechnical College* **35**, 135-140.

Mancini M, Rodríguez C, Prosperi C, Salinas V & Bucco C (2006). Main diseases of pejerrey (*Odontesthes bonariensis*) in central Argentina. *Pesquisa Veterinária Brasileira* **26**(4), 205-210.

Noga EJ (1993). Fungal and algal diseases of temperate freshwater and estuarine fishes. In **"Fish Medicine"** (M.K. Stoskopf, Ed.). WB Saunders Company, Philadelphia.

Ogbonna CIC & Alabi RO (1991) Studies on species of fungi associated with mycotic infections of fish in a Nigerian freshwater fish pond. *Hydrobiologia* **220**, 131-136.

Panchani K, Hanjavanit C & Kitancharoen N (2007). Aquatic fungi developing on eggs of tilapia *Oreochromis niloticus* Linn. and their control. 11th BRT annual conference Udonthani.

Prophet EB, Mills B, Arrington JB & Sobin LH (1992). Laboratory Methods in Histotechnology. Armed Forces Institute of Pathology, American Registry of Pathology, Washington. 279p.